

3-1974

## Phenotypic Males with 46, XX Karyotype: Report of Two New Cases

G. R. Rubio

Lester Weiss

J. F. Nunez

M. Saeed uz Zafar

Follow this and additional works at: <https://scholarlycommons.henryford.com/hfhmedjournal>

 Part of the [Life Sciences Commons](#), [Medical Specialties Commons](#), and the [Public Health Commons](#)

### Recommended Citation

Rubio, G. R.; Weiss, Lester; Nunez, J. F.; and Saeed uz Zafar, M. (1974) "Phenotypic Males with 46, XX Karyotype: Report of Two New Cases," *Henry Ford Hospital Medical Journal* : Vol. 22 : No. 1 , 13-20.

Available at: <https://scholarlycommons.henryford.com/hfhmedjournal/vol22/iss1/4>

This Article is brought to you for free and open access by Henry Ford Health System Scholarly Commons. It has been accepted for inclusion in Henry Ford Hospital Medical Journal by an authorized editor of Henry Ford Health System Scholarly Commons.

# Phenotypic Males with 46, XX Karyotype

## Report of Two New Cases

G. R. Rubio, MD,\* Lester Weiss, MD,\*\* J. F. Nunez, MD\* and  
M. Saeed uz Zafar, MD\*

*Two sex chromatin positive phenotypic males were found to have 46, XX karyotypes. Both had small testes and elevated gonadotropins with low testosterone levels. Semen analysis could not be obtained but one man claimed to have a daughter.*

*In one patient, mosaicism was suggested by the finding in a single cell of a chromosome morphologically resembling a Y. A second cell line was not found in the other patient.*

*Possible explanations for the development of a male phenotype in the absence of demonstrable Y chromosome include the existence of two cell lines or mosaicism, an autosomal sex determining gene and the translocation of a fragment of the Y chromosome to another chromosome.*

*It is possible that more than a single etiological mechanism accounts for the occurrence of this syndrome.*

---

\*Division of Endocrinology

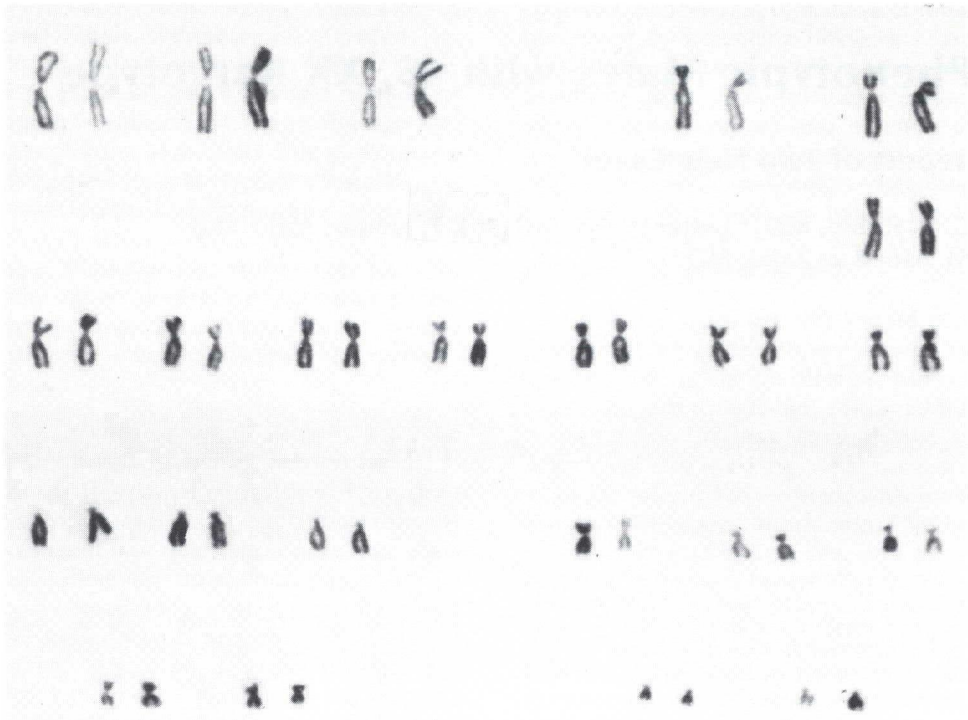
\*\*Cytogenetics Laboratory and Department of Pediatrics

Address reprint requests to Dr. Rubio at Henry Ford Hospital, 2799 West Grand Boulevard, Detroit, MI 48202.

THE primordial gonad of the human embryo identifiable by the fifth to seventh week of gestation is morphologically similar in both males and females. Further development of the medullary portion forms a testicle whereas an ovary results from dominant development of the cortical portion. Normally these changes are genetically determined by an XX or XY sex chromosome constitution. Abnormalities of the sex chromosomes are known to be associated with various types of gonadal dysgenesis; Turner's and Klinefelter's syndromes are examples.

Animal experiments and observations in patients with various sex chromosome abnormalities have led to the hypothesis that the genetic determinants required for the development of testicular structures reside near the centromere or in the short arm of the Y chromosome. The subsequent development of male primary sexual characteristics or male phenotype depends on the effect of fetal testicular secretions.

Nearly 50 cases of phenotypic males with 46, XX karyotypes have been reported in the world literature since the original report of 1964.<sup>1</sup> We are presenting two additional cases, their cytogenetic studies, and a review of pertinent recent literature.



**Figure 1**  
The karyotype of Patient One — 46, XX a normal female karyotype.

### Case Reports

**Case #1:** This man was first seen at the age of 37 with the complaint of infertility during nine years of marriage. Semen analysis elsewhere was said to have shown "few weak sperms". His potency was normal but libido had declined. He denied ethanol intake, visual difficulties or myotonia. There was no family history of hypogonadism. At the time of the patient's birth his father was 40 years old and his mother was 32. He was a short, normally proportioned Caucasian male, 66" tall, slightly obese, with male pattern scalp baldness and masculine body hair distribution. He had no gynecomastia. The penis was 5 cm long and the normally rugated scrotum contained two soft small testes measuring 2 x 1.5 cm. The prostate gland was abnormally small. Routine laboratory studies were normal. BMR was -25%, cholesterol 193 mg% and skull roentgenogram was normal. Twenty-four hour urinary 17 ketosteroid level was 9.5 mg, while urine gonadotropins were elevated above 128 muu (Mouse Uterine Units) with a urinary creatinine of 898 mg.

Treatment with testosterone and dessicated thyroid produced improvement in vitality and sexual performance. No additional medical treatment was required for 14 years but in 1970 a breast lipoma was removed. At that time buccal smear was reported to have 20% of cells positive for nuclear chromatin. Because the somatic features were not characteristic of Klinefelter's syndrome, cytogenetic studies were undertaken.

**Case #2:** This man, a 43-year-old Negro male, was hospitalized during an acute bout of recurrent pancreatitis related to ethanol ingestion. An incidental finding was bilateral soft, small testes. His height was 68.5", weight 141 lbs. He had extensive male pattern baldness with male distribution of pubic and axillary hair. No cataracts, gynecomastia, hepatomegaly or splenomegaly were detected. The penis was normal and the testicles each measured 2.5 x 1 cm. Prostate was small and flat. Both fourth metacarpals were abnormally short and there was a simian crease in the right palm.

## Phenotypic Males with 46, XX Karyotype

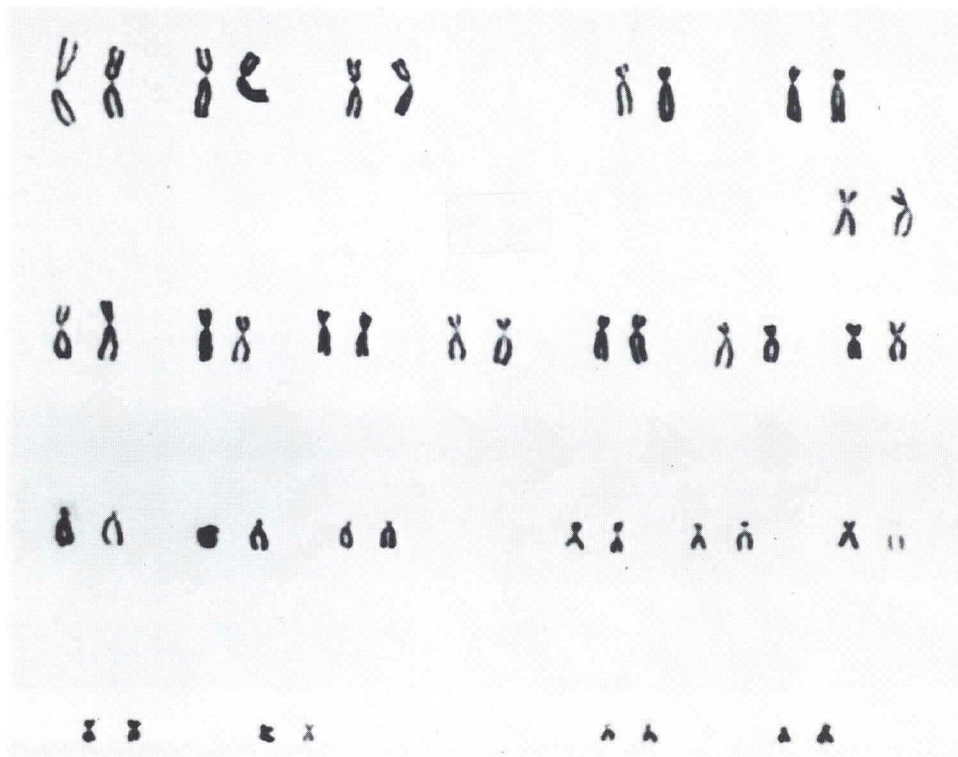


Figure 2  
The karyotype of Patient Two — 46, XX a normal female karyotype.

His first marriage, of one year's duration, had been infertile, while the current wife had become pregnant after 15 years of marriage and gave birth to a healthy female child. The patient denied impotence. At the time of the patient's birth his father was 24 years old and his mother was 18.

Complete blood count was normal except for leukocytosis with a left shift. Urinalysis, serum electrolytes, prothrombin time, BUN, SGOT, alkaline phosphatase and bilirubin were normal. Elevated serum and urine amylase were consistent with the diagnosis of acute pancreatitis. Serum protein electrophoresis disclosed elevated gammaglobulins and decreased albumin. BSP retention was 5.5% while glucose tolerance was normal.

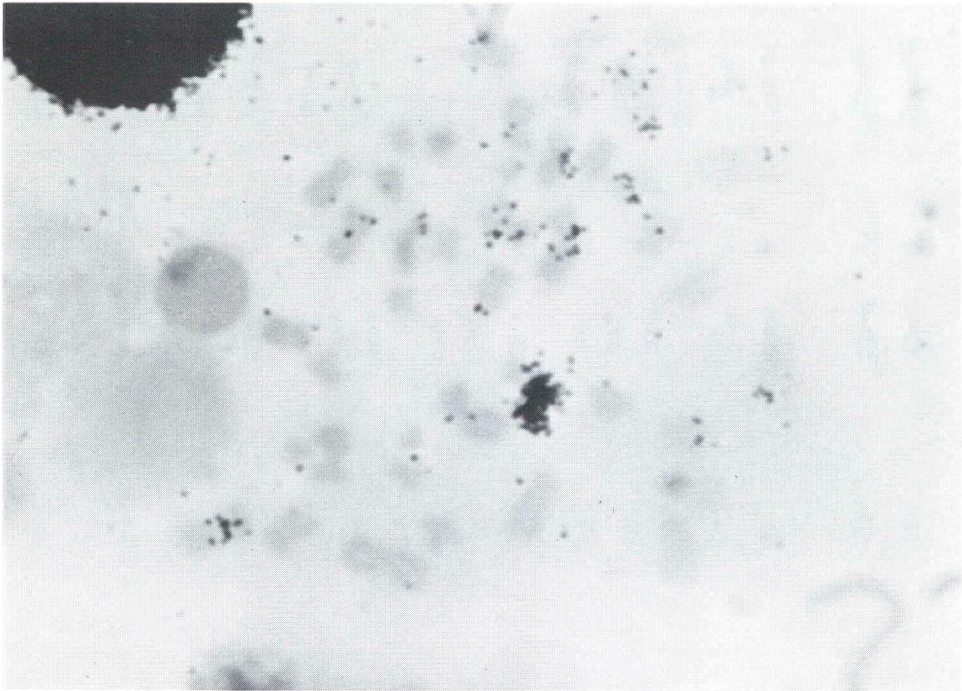
Twenty-four hour urinary testosterone was 11.6 ug, 17 ketosteroids 6.6 mg, and 17-hydroxycorticosteroids 20.4 mg with urinary creatinine 1123 mg. Urinary gonadotropins were elevated above 96 muu. IVP showed

bilateral double collecting systems while other radiological examinations revealed patchy demineralization of the skull, calcified falx cerebri, thinning of bone cortices suggestive of osteoporosis and bilateral short metacarpals. Buccal smear disclosed 31% of cells positive for sex chromatin bodies.

The patient was unwilling to submit to semen analysis or testicular biopsy. Efforts to obtain blood specimens from the daughter for paternity studies were unsuccessful.

### Cytogenetic Studies

Buccal smears from both men were chromatin positive (31% in Patient One and 20% in Patient Two). Karyotype analysis of 100 peripheral blood lymphocyte metaphases from Patient Two revealed 46, XX karyotype (Figure 1). In no cell was a chromosome seen with the morphologic characteristics of a Y chromosome. Analysis of 60 metaphase cells on peripheral blood lymphocytes from Patient One revealed his karyotype to be 46, XX (Fig-



**Figure 3**  
**Autoradiography of metaphase from Patient One labeled with tritiated thymidine demonstrating late labeling X.**

ure 2). One cell was found in which there was a chromosome with the morphologic characteristics of the Y chromosome.

However, this chromosome did not have the fluorescence pattern of the Y chromosome. Of two hypomodal cells found, one was missing a C group chromosome, and the other a D group chromosome. One hundred metaphase plates were examined from fibroblast cultures obtained from a skin biopsy from Patient One and one hundred from Patient Two. All cells from Patient One except one were karyotyped as 46, XX; one cell was 45, XX-E. All cells from Patient Two were karyotyped as 46, XX. Some cells from each patient were found with four satellited G chromosomes; other cells had six identifiable satellited D group chromosomes.

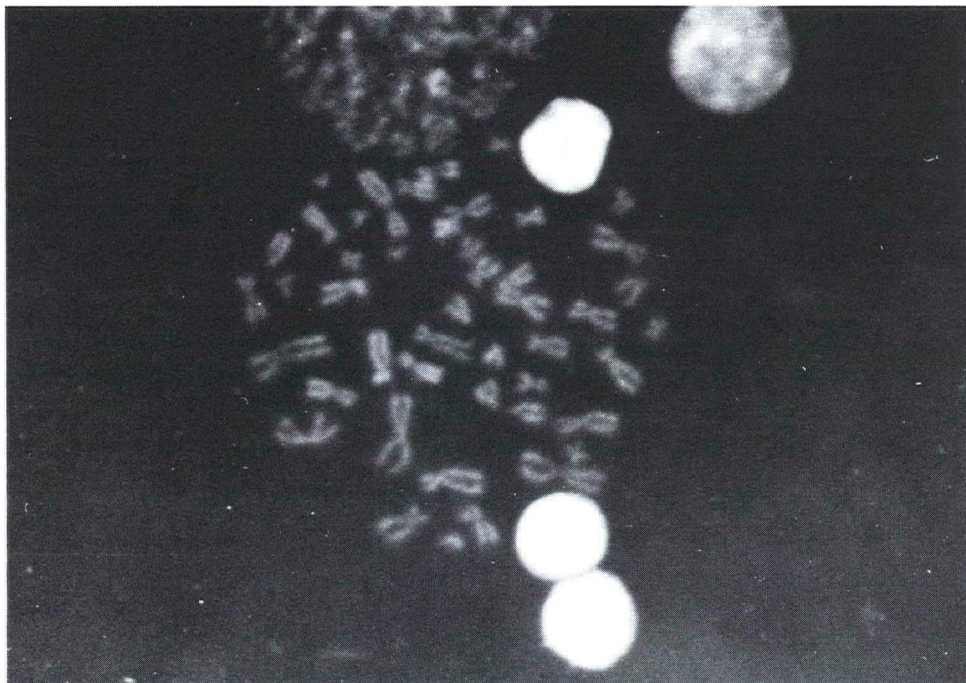
Autoradiographic studies using tritiated thymidine demonstrated a late labelling X chromosome in each patient (Figure 3).

Peripheral blood smears from both patients were examined for the presence of Y chromo-

some fluorescence according to the method of Pearson and Bobrow.<sup>2</sup> Interphase polymorphonuclear leukocytes and lymphocytes were examined and in no instance was the fluorescence typical of the Y chromosome found.

Metaphase chromosomes were stained with 0.05% quinacrine mustard according to the technique of Caspersson et al<sup>3</sup> and examined with a Zeiss mercury lamp fluorescence microscope using a DG12 excitor and 53/54 barrier filters. One hundred metaphase lymphocytes from Patient One and the same number from Patient Two were studied. In no instance anywhere in the genome did we observe the brightly fluorescent material from the distal two-thirds of a Y chromosome. Figure 4 is a photograph of a metaphase cell and Figure 5 a karyotype of a normal male demonstrating the characteristic fluorescence of the chromosomes and particularly the distal two-thirds of the Y chromosome. These bands are characteristic and make identification of individual chromosomes possible.

## Phenotypic Males with 46, XX Karyotype



**Figure 4**

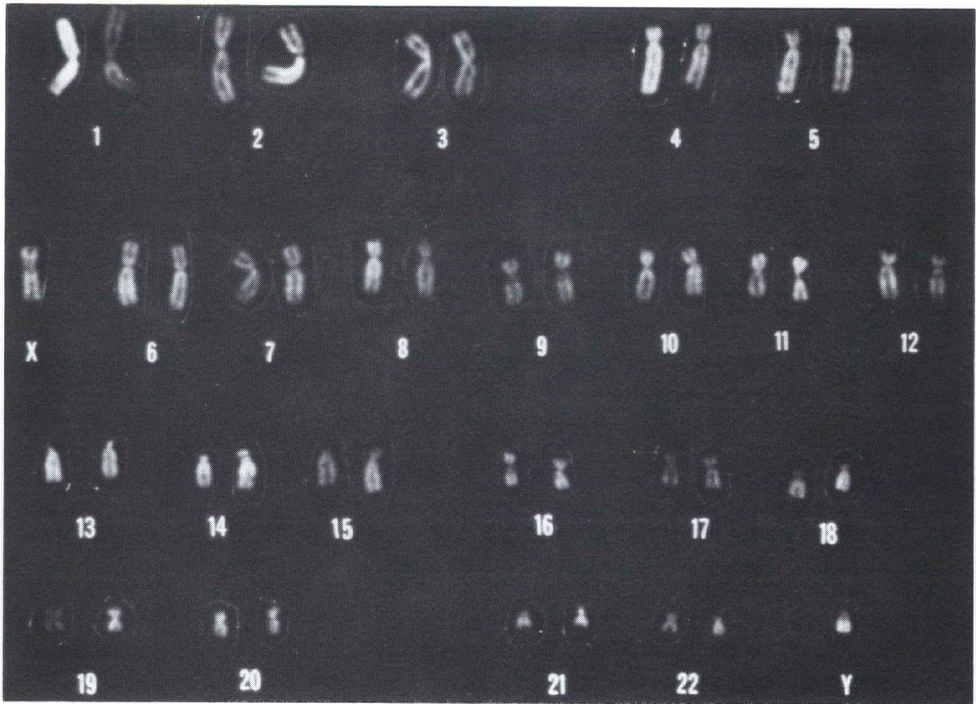
**Metaphase from Patient One stained with quinacrine mustard. The brightly fluorescent distal portion of the Y chromosome is not present as a translocation.**

### Discussion

Increasing awareness of the existence of individuals with male phenotype and 46, XX karyotype has led to the discovery of nearly 50 cases since the first report in 1964.<sup>1</sup> These patients may have been classified previously as cases of Klinefelter's syndrome which is also characterized by hypergonadotrophic hypogonadism and sex chromatin positivity. The clinical features of phenotypic males with XX karyotype somewhat resemble those of Klinefelter's syndrome in regard to gynecomastia, male psychosexual orientation, normal to low intelligence, sparse sexual hair, testicular histology and hormone levels. However, XX males with abundant body hair growth have been described in the comprehensive literature review by de la Chapelle.<sup>4</sup> There are

also some striking differences in somatic features. XX males usually have normal body proportions, muscular development and fat distribution. Their mean height is significantly shorter than XXY males and they are slightly shorter than the mean for normal males. Psychosis has not been reported in XX males. There is on record a set of identical twins with the condition.<sup>5</sup>

An assortment of associated malformations has been described in XX males including renal anomalies, bilateral hydrocele, clinodactily of the fifth finger, deafness pseudo-truncus arteriosus, enophthalmus and microcephaly. No skeletal abnormalities have been reported and dermatoglyphic studies have disclosed no consistent abnormalities al-



**Figure 5**  
**Fluorescent normal male karyotype metaphase showing bright distal portion of the Y chromosome.**

though unusual patterns have been reported in three cases. Our Patient Two had a double urinary collecting system, bilateral short fourth metacarpals and a simian crease on the right hand. The alleged paternity of Patient Two requires proof but does not warrant the threat to his family structure that its demonstration might imply. No information is available concerning parental consanguinity of siblings of either patient.

The use of quinacrine mustard staining and fluorescence microscopy has made it possible to identify visually each chromosome pair according to specific banding patterns.<sup>6</sup> The bright fluorescence of the distal two-thirds of the Y chromosome is easily identified (Figure 5) facilitating the identification of mosaicism or Y autosome translocations. No Y chromosome fluorescence was detected

in either patient reported here, but a chromosome resembling a Y was seen in a single cell from Patient One. Several theories have been proposed<sup>4</sup> to explain the development of testes and male phenotype in such patients.

1. *The gene theory* suggests a mutation of the postulated autosomal sex determinants. It is conceivable that autosomal genes can influence maleness in men, as in Saanen goats and some mice.<sup>7,8</sup> The lack of parental consanguinity and of the expected high incidence of XX males among sibs is evidence against autosomal dominant inheritance. The normal sex ratio in most families of XX males studied is further evidence against autosomal dominant transmission.<sup>4</sup> However, Berger et al,<sup>9</sup> reported a family in which an XX male and an XX

## Phenotypic Males with 46, XX Karyotype

true hermaphrodite occurred in a sibship and Kasdan et al<sup>10</sup> have presented the first report of three XX phenotypic males in one family, an XX true hermaphrodite, an XX brother and an XX infertile paternal uncle. The authors suggest the possibility that two separate male determinants were operative in this family. The data from our patients lend neither supporting nor refuting evidence to this theory.

2. *The interchange theory:* Ferguson-Smith<sup>11</sup> has proposed the hypothesis of a translocation of all or part of the Y chromosome to another chromosome, possibly the X, which could occur during X-Y chromosome association during the first meiotic division of the human male. Studies of Y chromosome length in the fathers of XX males have failed to show the shortening expected if translocation of Y material had occurred.<sup>4</sup> The blood group Xg linked to the X chromosome permits tracing the source of this chromosome to either parent. Supporting the interchange hypothesis is the demonstrated atypical inheritance of the blood group Xg in three XX males and in several normal families. However, alternate explanations for the Xg findings are possible based on color vision studies as well as the inheritance of Xm proteins which, like the Xg blood groups, are linked to the X chromosomes.<sup>4</sup> We did not test these possibilities in any of our patients.
3. *The mosaicism theory:* This theory proposes that a cell line containing a Y

chromosome could have become lost or extremely circumscribed.

- a. Mitotic double nondisjunction of a normal XY zygote produces an XX and YY line or single nondisjunction resulting in an XXY and a Y or both. The YY or YO lines being lethal would be eliminated and the remaining XXY or XY line would be lost.
- b. An XX ovum fertilized by normal Y containing sperm produces an XXY zygote. A later mitotic error would produce an XX and XXYY lines, the latter of which is eliminated.

Waldemar et al<sup>12</sup> were able to demonstrate quinacrine mustard stained fluorescence in 29% of Sertoli cells studied in an XX male. In this case a Y chromosome was described in a single peripheral blood leukocyte. As pointed out by the authors, other fluorescent bodies can simulate the Y chromosome. However, the Y chromosome is not always fluorescent and it is possible that the XY Sertoli cell lines of mosaic cases could exhibit relatively poor growth in cell cultures, thus offering an explanation for the difficulty in demonstrating Y chromatin in suspected mosaicism. Our Patient One may well represent a similar example of this type as suggested by the finding of one chromosome morphologically similar to Y but nonfluorescent. This is compatible with the mosaicism theory, since the sex determining locus of the Y chromosome lies in the non-fluorescent short arm.<sup>13</sup> Thus, failure to demonstrate the Y chromosome is not proof of its absence.

## References

1. de la Chapelle A, Hortling H and Niemi M: XX sex chromosomes in a human male, first case. *Acta Med Scand* **412** (Suppl): 25, 1964
2. Pearson PL and Bobrow M: Technique for identifying Y chromosomes in human interphase nuclei. *Nature* **226**:78, 1970



Rubio, Weiss, Nunez and Zafar

3. Caspersson T, Zech L and Johansson C: Analysis of the human metaphase chromosome set by aid of DNA-binding fluorescent agents. *Exp Cell Res* **62**:490, 1970
4. de la Chapelle A: Analytic review: Nature and origin of males with XX sex chromosomes. *Amer J Hum Genet* **24**:71, 1972
5. Nicolis GL, Hsu LY, Sabetghadam R et al: Klinefelter's syndrome in identical twins with the 46, XX chromosome constitution. *Amer J Med* **52**:482, 1972
6. Caspersson T, Zech L, Johansson C and Modest ES: Identification of human chromosomes by DNA-binding fluorescing agents. *Chromosome* **30**:215, 1970
7. Sollner M, Padeh B and Wysoki M: Cytogenetics of Saanen goats showing abnormal development of the reproductive tract associated with the dominant gene for Polledness. *Cytogenetics* **8**:51, 1969
8. Cattanaach BM, Pollard CE and Hawks SG: Sex reversed mice: XX and XO males. *Cytogenetics* **10**:318, 1971
9. Berger R, Abonyi D, Nodot A et al: Hermaphroditisme vrai et "garçon XX" dans une fratrie. *Rev Europ Etudes Clin Biol* **15**:330, 1970
10. Kasdan R, Nankin HR, Troen P et al: Paternal transmission of maleness in XX human beings. *New Eng J Med* **288**:539, 1973
11. Ferguson-Smith MS: X-Y chromosomal interchange in the etiology of true hermaphroditism and of XX Klinefelter's syndrome. *Lancet* **2**:475, 1966
12. Waldemar AP, Chen Y and Chen H: Case report: Presence of brightly fluorescent material in testes of XX males. *J Med Genet* **10**:170, 1973
13. Jacobs PA and Ross A: Structural abnormalities of the Y chromosome in man. *Nature* **210**:352, 1966